

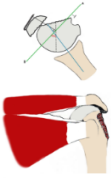Arthroscopic Transosseous Suture Reduction and Fixation Of Avulsed Displaced Greater Tuberosity Fracture; three techniques of fixation transverse, longitudinal and mattress are used according to the pathology

Basim Fleega MD,
Shoulder Service, Global Orthopedic Clinic Giza, Cairo, EGYPT
Ibnsina university of medical and pharmaceutical sciences

Aim

In this study we will present the three new techniques of arthroscopic reduction and transosseous suture fixation as well as evaluation of the functional and radiographic results of a series of mostly old patients with posttraumatic displaced two parts greater tuberosity fractures of the proximal humerus. The results of conservative treatment of the proximal humerus fractures are not satisfactory. Open reconstruction and rigid internal fixation as well as arthroscopic-assisted reduction and internal fixation are only possible in selected cases, mostly young patients. Old patients with osteoporotic, comminuted bone accounts for 70% of the cases.

DISPLACED 2 PARTS FRACTURE



Displaced greater tuberosity
loss of external rotation (POSTERIOR)
limitation of elevation (SUPERIOR)
impingement problems (SUPERIOR)

TREATMENT OPTIONS

- 1 - Conservative
- 2- Open reconstruction and rigid internal fixation
- 3 - Arthroscopic-assisted reduction and internal fixation

LITERATURE: ARTHROSCOPIC TREATMENT OF DISPLACED GREATER TUBEROSITY FRACTURE



Arthroscopic-assisted reduction and internal fixation
selected cases
mostly young patients
not in osteoporosis

• These techniques are not applicable in most of the patients who are old patients with osteoporotic, comminuted bone (70% of the cases).

**New Technique
ARTHROSCOPIC TRANSOSSEOUS SUTURE
FIXATION**

- Developed **2011**
- Since then most of the fractures are done using this technique




Methods

The arthroscopic transosseous suture fixation technique of avulsed greater tuberosity fracture starts by reduction of the upwards and medially displaced greater tuberosity to its anatomical position and fix it with longitudinal, horizontal and mattress sutures.

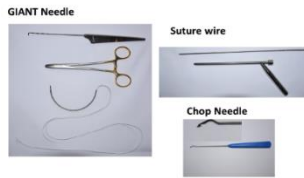
ARTHROSCOPIC TRANSOSSEOUS SUTURE FIXATION

The aim is to reduce the upwards and medially displaced greater tuberosity to its anatomical position and making a longitudinal or horizontal transosseous suture fixation or both

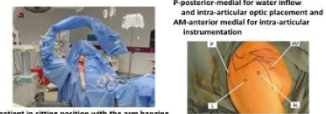

1. Longitudinal (Giant needle System) 2. Horizontal (Suture wire system)

THREE ARTHROSCOPIC SYSTEMS

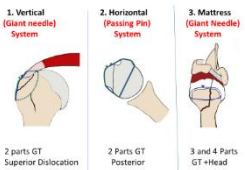


POSITION AND PORTALS



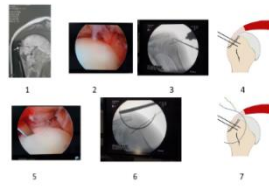
patient in sitting position with the arm hanging for standard neutral rotation or lower arm on the thigh for stable internal rotation position.

THREE TECHNIQUES OF TRANSOSSEOUS SUTURE FIXATION

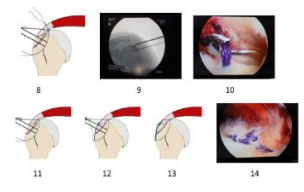


2 parts GT Superior Dislocation 2 Parts GT Posterior 3 and 4 Parts GT +Head

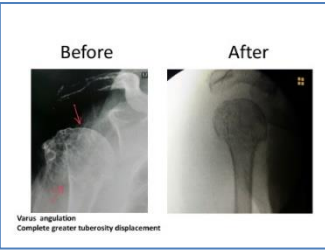
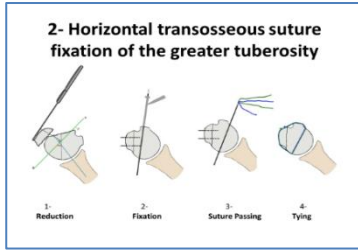
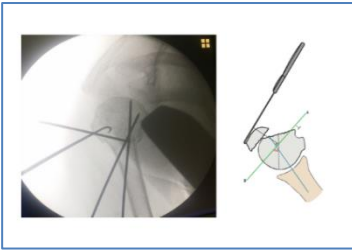
1. SHORT LONGITUDINAL (Transosseous Giant Needle)



1. SHORT LONGITUDINAL (Transosseous Giant Needle)

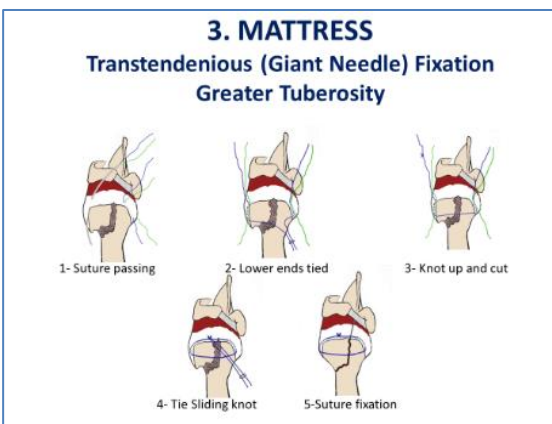


Giant Needle Transosseous Suture Fixation: Horizontal Suture Fixation: A small hook is passed through the anterior lateral instrumentation portal and with the aid of an image intensifier the greater tuberosity is pulled laterally and downwards till it is in an anatomical position then it will be fixed with two wires from lateral. The Giant Needle is then passed through the skin then through the head out. The two ends of the suture will be pulled through the instrumentation portal and tied. Then the two K-wires are removed.



HORIZONTAL SUTURE FIXATION: A small hook is passed through the anterior lateral instrumentation portal and with the aid of an image intensifier the greater tuberosity is pulled with external rotation of the head lateral and forwards till it is in an anatomical position at this point by pulling the fragment in its anatomical position with the sharp hook it will be fixed with two wires from lateral. A Wire Suture Passer is drilled through the head from anterior to posterior thus passing two sutures through the head. The anterior and posterior ends of the suture are then pulled out through the instrumentation portal and a sliding knot is passed to fix the greater tuberosity to the shaft.

MATTRESS SUTURE FIXATION: Two giant needles are used to pass two sutures through the subscapularis and infraspinatus tendons. The lower ends of both sutures are pulled with an arthroscopy hook through the instrumentation portal and tied together firmly. Then the upper end of the suture passing through the greater tuberosity tendon is pulled to move the already made knot between the lower ends inside the shoulder through the greater tuberosity-tendon junction and out through the instrumentation portal. Then cut the knot to have a knotless suture through the tendons and its two ends are outside the instrumentation portal. The two upper suture ends are pulled out through the instrumentation portal and a mattress suture is made to fix the two tuberosities to each other using the one way secured sliding giant knot technique. The head should be in neutral rotation with the arm hanging while making the knot. We now have a horizontal suture fixing the greater tuberosity and a mattress suture securing the fixation.



24 patients (12 males and 12 females) with a specifically defined displaced fracture of the greater tuberosity underwent arthroscopic reduction and transosseous sutures fixation. The average age was 56 years (between 21 and 79). 66% were above 50 years of age. They were examined with an average follow up of two and a half years (between 12 and 83 months). Follow-up radiographs were assessed for fracture consolidation, malunion, nonunion, heterotrophic ossification, and signs of impingement. All displaced fractures were reduced fixed with number 2 non-absorbable sutures. Rehabilitation exercises were started after a postoperative immobilization period of 3 to 4 weeks.

- ### POSTOPERATIVE REHABILITATION
- **TWO WEEKS** IMMOBILIZATION IN A SLINGE
 - **TWO WEEKS** PASSIVE SELF-ASSISTED EXERCISES
 - **X- RAY**
 - **FOUR WEEKS** COMBINED PASSIVE STRETCHING AND ACTIVE SELF-ASSISTED EXERCISES
 - **FOUR WEEKS** AGGRESSIVE ASSITED STRETCHING AND STRENGTHENING EXERCISES

Results

Using Neer classification excellent results were present in all cases of the two parts fracture. All fractures were united within four weeks, no nonunion, no heterotrophic ossifications and no osteoarthritis or avascular osteonecrosis was detected. Three men and one women active athletes were able to go back to their previous performance.

Conclusions

The clinical and radiographic result strongly encourage using the arthroscopic transosseous suture fixation techniques to treat displaced greater tuberosity fractures especially in old age patients or patients with osteoporosis. It is the only method with very good results in this group of patients.