



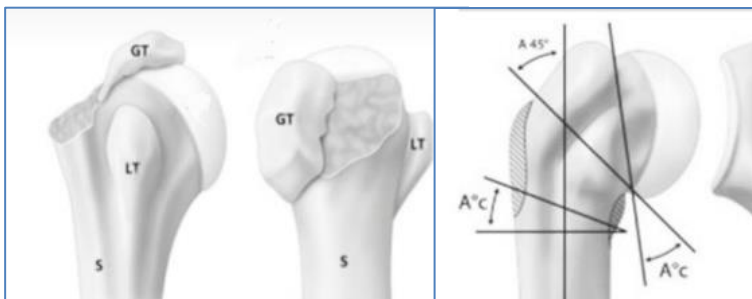
ARTHROSCOPIC REMOLDING OF PROXIMAL HUMERUS MALUNITED FRACTURES WITH LIMITATION OF MOTION AS AN ALTERNATIVE TO HEAD PROSTHESIS.

Ahmed Kandil MD, Basim Fleega MD

Global Orthopedic Clinic Giza , Cairo Egypt/Orthopedic Department Alexandria University Medical School Egypt

Aim

The main symptoms of malunion of proximal humeral fractures are loss of external rotation due to posterior malunion of the greater tuberosity, pain, subacromial impingement and limited joint range of motion due to proximal overhead apex displaced malunion of the greater tuberosity or malunited surgical neck fracture.

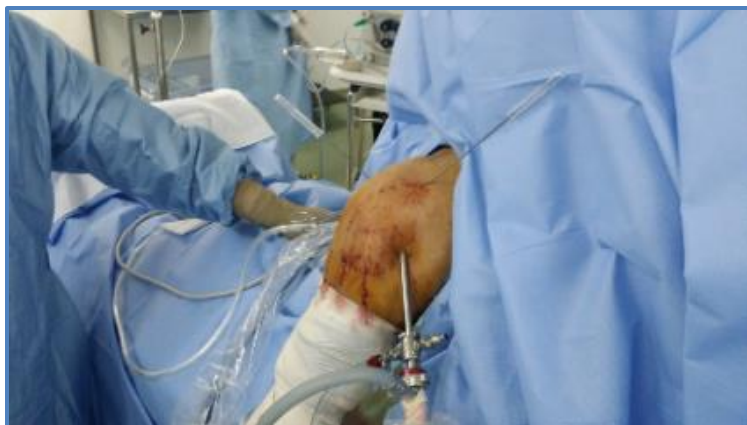

Most of the cases are treated with hemi or total arthroplasty. In this presentation we will demonstrate an arthroscopic procedure, developed by the second Author, to reconstruct the anatomy for regaining the external rotation and elevation range of motion and daily function demands of the shoulder.

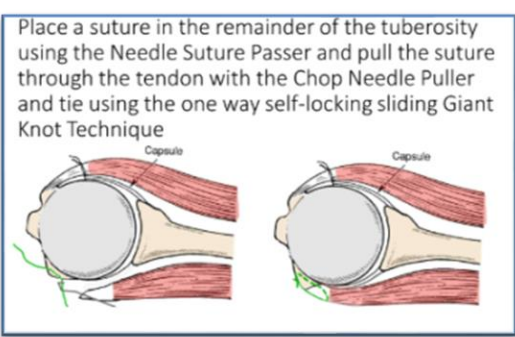
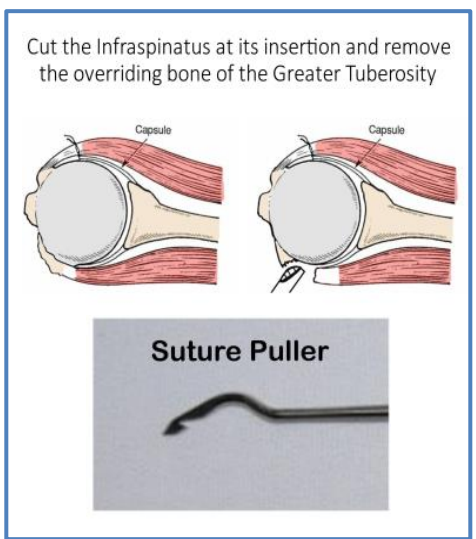
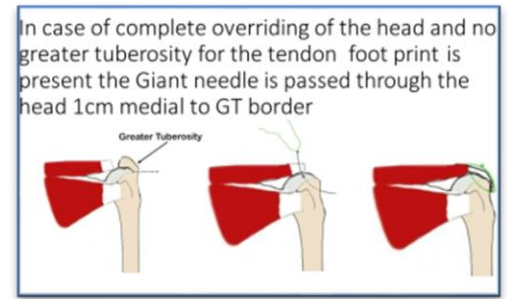
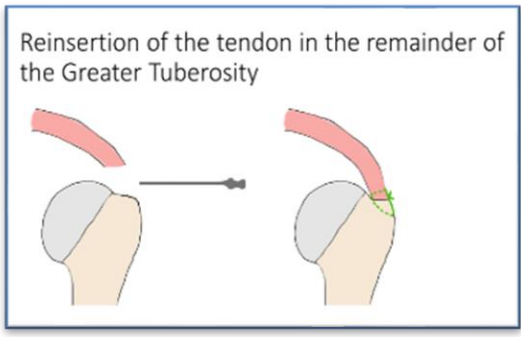
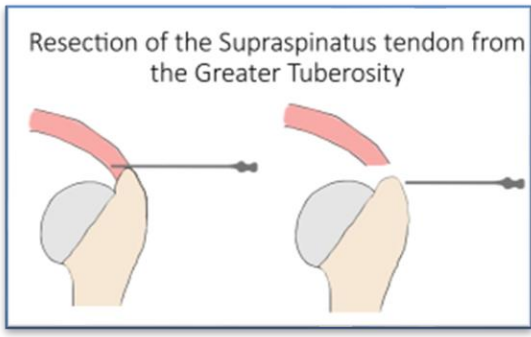
Methods

Twenty-five cases were treated with the arthroscopic remodeling technique of malunited proximal humeral fractures. The supraspinatus and infraspinatus are resected from the bony attachment on the proximal humerus, then with an acromionizer the greater tuberosity above the head *vivo* is resected and the part of the posteriorly malunited greater tuberosity causing loss of the external rotation due to hinging of the bone on the posterior rim of the glenoid will be removed till the external rotation is freed.

An anterior acromioplasty is also done to increase the subacromial space. After that the resected part of the infraspinatus and the supraspinatus tendons will be refixed to the greater tuberosity and the posterior head with transosseous sutures using the Giant needle technique and the suture passer wire.



The procedure was done in a sitting position with the arm hanging.



Results

The follow up of the patients showed an average increase in the range of motion of elevation to 155 degrees and external rotation to 56 degrees active and passive. The preoperative pain was dramatically improved. All patients returned doing all needed daily living activity and limited sports activity.

**TWENTYFIVE CASES POST OPERATIVE RESULTS
42 MONTHS AV. FOLLOW UP**

- **ELEVATION** average increase 55 degrees
- **EXTERNAL ROTATION** average increase 31 degrees
- **PAIN** no motion pain after surgery
- **SPORT** Returned (with limitation)

Conclusions

The arthroscopic remodeling of malunited proximal humeral fracture can be a sound alternative to head replacement arthroplasty in cases with preserved head curvature