



PSI Guided Fracture Reconstruction using opposite normal shoulder CT measurements
Moataz Eldeeb MD, Basim Fleega MD
 Shoulder Service Global Orthopaedic Clinic Giza, Cairo, EGYPT/ Alazhar University Medical College Hospital,
 Orthopedic Dept. Dumiat, EGYPT

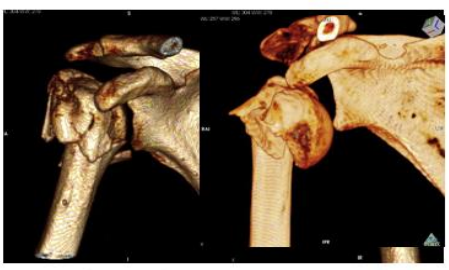Aim

arthroscopic reconstruction of proximal humeral fracture is a new immerging technique of treatment which is valuable especially in osteoporotic old patients. To ease the procedure, PSI models based on CT measures were used to guide the procedure.

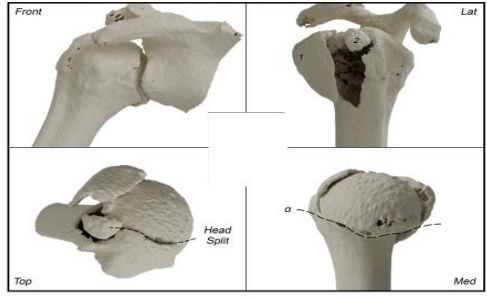
Methods

During the last 4 years 13 cases of three to four parts fracture were done using the PSI model. A CT 3D assessment scan is done to the fractured shoulder and a PSI model exactly same as the original fractured proximal humerus in shape and size is made. The model is then studied preoperatively, and a fracture reduction plan is made before surgery. During the surgery the sterilized model is used as a guide for closed reduction and percutaneous fixation. Then arthroscopic suturing of the fracture is made to fix the fragments together in the anatomic position followed by removal of the percutaneous wires according to the four techniques described below. The age of the patients was between 52 and 80 years and 80% had osteoporosis.

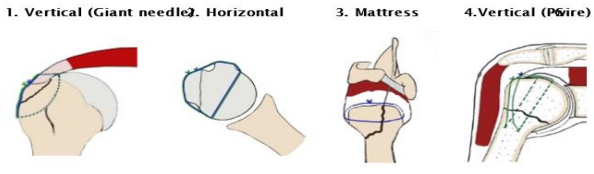
ASSESSMENT



Preoperative and Intraoperative reduction Guide Model



FOUR TECHNIQUES OF TRANSOSSEOUS SUTURE FIXATION (Arthroscopy Journal 2020)



Arthroscopic Reduction and Transosseous Suture Fixation of Avulsed Displaced Shoulder Greater Tuberosity Fracture
 Basim A M Fleega, M D, Saad Karim, M D
 Affiliations: * equipped
 PMID: 33736220 PMCID: PMC7953264 DOI: 10.1016/j.ajot.2020.10.074

Arthroscopic Surgery done (13 cases)

- Giant Needle repair Longitudinal suture fixation **6 cases**
- Suture wire Horizontal suture fixation **2 cases**
- Combined suture wire horizontal +giant Needle longitudinal repair **5 cases**

POSTOPERATIVE REHABILITATION

- **TWO WEEKS** IMMOBILIZATION IN A SLINGE
- **TWO WEEKS** PASSIVE SELF-ASSISTED EXERCISES
- **X- RAY**
- **FOUR WEEKS** COMBINED PASSIVE STRETCHING AND ACTIVE SELF-ASSISTED EXERCISES
- **FOUR WEEKS** AGGRESSIVE ASSITED STRETCHING AND STRENGTHENING EXERCISES



Results

9 cases of the of the 13 had a good reconstruction and healing 3 cases had a fairly good refixation of the fragments and one case failed and got a hemiarthroplasty. The range of motion was regained to 90% in half of the cases, but all the patients were satisfied with the surgery and were able to use the arm without pain for daily living needs.

- BEFORE ARTHROSCOPIC SUTURE TRANSOSSEOUS RECONSTRUCTION →

- AFTER RECONSTRUCTION →

3 Months After Surgery

REVIEW OF 13 CASES, AVERAGE FOLLOW UP 31 MONTHS (Clinical and Radiological)

- 9 females (70%) 4 males (30%)
- **average age: 59 years** (between 52 and 80 years)
- There were 9 cases 3parts and 4 cases 4 parts Fracture
- Arthroscopic transosseous, number 2 non-absorbable suture fixation repair
- 80% were cases with osteoporosis

RESULTS and CONCLUSION

| | |
|--|---|
| <p>Neer classification</p> <p>Excellent results</p> <ul style="list-style-type: none"> • 7 <p>Satisfactory results</p> <ul style="list-style-type: none"> • 5 <p>Unsatisfactory</p> <ul style="list-style-type: none"> • 1 <ul style="list-style-type: none"> • NO COMPLICATIONS • NO SYMPTOMS OF IMPINGEMENT • NORMAL RANGE OF MOTION | <p>CONCLUSION</p> <ul style="list-style-type: none"> • Excellent clinical and radiological outcome • Applicable in all cases of osteoporosis or bone comminution • One day surgery , accepted by most of the old patients |
|--|---|

Conclusions

Using the PSI model as a guide in arthroscopic reconstruction of the three to four parts proximal humeral fracture of the shoulder can very much ease the arthroscopic reduction and suture transosseous fixation of the fragments.