



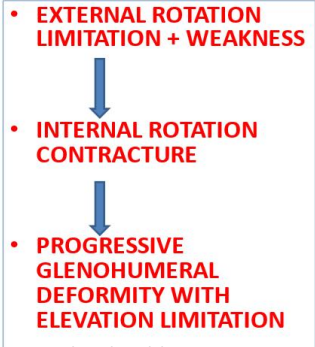
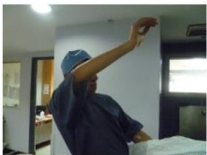
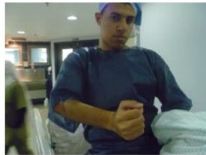Reconstruction of Erb's Shoulder in patients above 14 years of age; arthroscopic reconstruction technique

Mohanad Al-Bayati MD, Basim Fleega MD
Shoulder Service Global Orthopaedic Clinic Giza Cairo, EGYPT

Aim

Erbs Palsy Problem

External rotation weakness secondary to obstetrical brachial plexus palsy leads to Internal rotation contracture of the shoulder causing functional and cosmetic problems. The persistent muscle imbalance and soft tissue contracture can lead to progressive glenoid humeral joint deformity which if not treated early can lead to complete disfunction of the shoulder in mature young patens.



A new arthroscopic technique developed by the second Author to reconstruct the shoulder in patients above 14 years of age and its results will be presented.

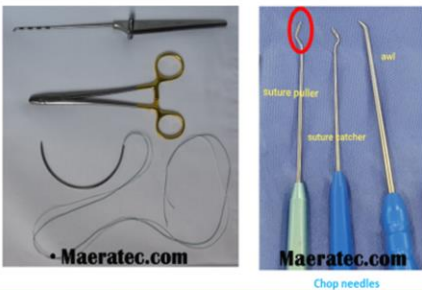
The bony deformity is; mainly a decrease in the head curvature and rotation (affecting range of motion usually loosing 20-50% of the elevation and 50% of the external rotation). The about 5 to 10 mm superior protrusion of the greater tuberosity causes impingement on elevation above 70 degrees. Added to that is the soft tissues changes as contraction of the anterior capsule and subscapularis, the disuse weakness of the infraspinatus, the elongation of the supraspinatus and the contracted inferior capsule

(Limited goals) 2 Bone and 3 Soft Tissue Reconstruction

- DECOMPRESSION OF THE SUBACROMIAL SPACE (space for more elevation)**
 - 1- Anterior Acromioplasty
 - 2- Resection of Greater tuberosity protrusion
- ELONGATION OF THE SUBSCAPULARIS (Increase the range of external rotation)**
 - 3- oblique cut through the subscapularis
- RELEASE OF THE INFERIOR CAPSULE (Give way for more elevation)**
 - 4- capsulotomy

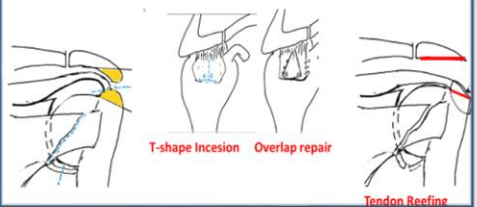Methods

Arthroscopic Transosseous suture fixation



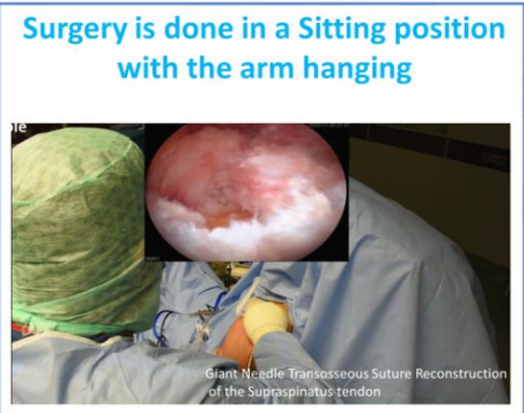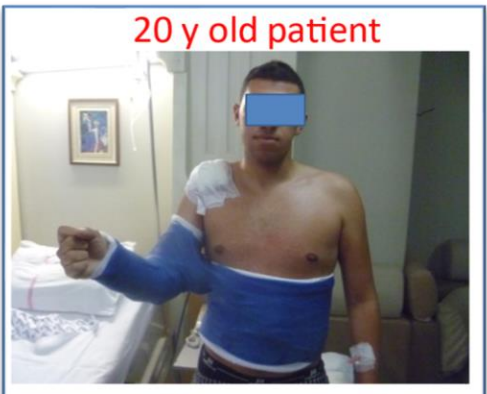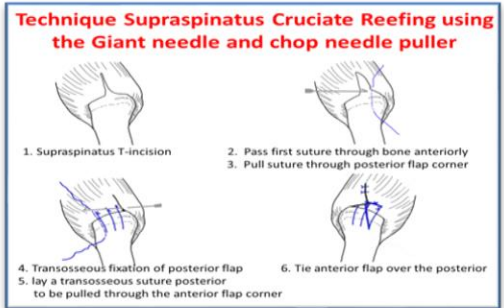
Redundant Capsule and Supraspinatus Tendon

5- T-type cruciate supraspinatus tendon-capsule reefing

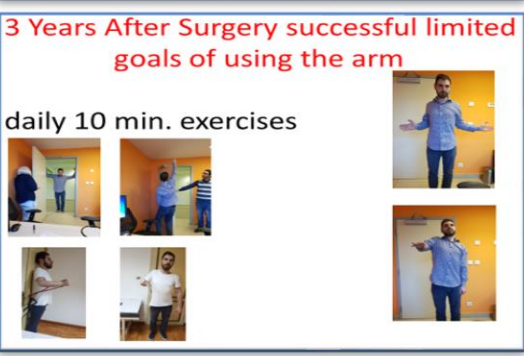



The arthroscopic surgery addresses the bony deformity by resecting the head overriding part of the greater tuberosity and an anterior acromioplasty to allow increasing the range of elevation and treat the bony impingement. A cruciate repair of the superior capsule and tendon allow more stability to the head and decreases superior migration on elevation. Release of contractions of the anterior capsule and elongation of the subscapularis through an oblique cut will allow more range of motion in external rotation. Also releasing the inferior capsule leads to increase in elevation. After this all arthroscopic procedure the shoulder is immobilized in 50 degrees external rotation and 2 degrees abduction for 6 weeks followed by 3 to 12 months rehabilitation.



- Adults Shoulder after surgery**
- **IMMOBILIZATION IN AN ABDUCTION BRACE FOR 6 WEEKS**
 - **CONTINUE EXERCISES 15 MINUTES DAILY**
 - **One year daily Exercises 30 min**



Results

The surgery was done to 5 patients with average 27 months follow up, minimum 12 months. Average age was 17 years. All had the above procedure and two had open additional latissimus dorsi transfer. All patients were able to achieve the limited goals of the surgery to completely use the arm in daily living after long years of no use and no difference in the results was noticed between cases with latissimus dorsi transfer and those without.

Conclusions

Arthroscopic limited goals treatment of Erbs Palsy in nonfunctioning arm in adults

- less invasive technique
- Good results are possible
- Postoperative daily rehabilitation is essential
- Results remain only with continuing exercises
- Arthroscopic reconstruction is an option to consider in non functioning Erbs arm in adults